Cardiovascular Pathology 72 (2024) 107646

Contents lists available at ScienceDirect

Cardiovascular Pathology

journal homepage: www.elsevier.com/locate/carpath

Original Article

A machine learning algorithm improves the diagnostic accuracy of the histologic component of antibody mediated rejection (AMR-H) in cardiac transplant endomyocardial biopsies

Matthew Glass[1,2], Zhicheng Ji[3], Richard Davis[4], Elizabeth N. Pavlisko[1,4], Louis DiBernardo[4], John Carney[4], Gregory Fishbein[5], Daniel Luthringer[6], Dylan Miller[7], Richard Mitchell[8], Brandon Larsen[9], Yasmeen Butt[9], Melanie Bois[10], Joseph Maleszewski[10], Marc Halushka[11], Michael Seidman[12], Chieh-Yu Lin[13], Maximilian Buja[14], James Stone[15], David Dov[1,16], Lawrence Carin[1,16], Carolyn Glass[1,4,*]

[1] *Duke Division of Artificial Intelligence and Computational Pathology, Duke University Medical Center, Durham NC, USA*
[2] *Department of Anesthesiology, Duke University Medical Center, Durham NC, USA*
[3] *Department of Biostatistics and Bioinformatics, Duke School of Medicine, Durham NC, USA*
[4] *Department of Pathology, Duke University Medical Center, Durham NC, USA*
[5] *Department of Pathology, University of California at Los Angeles, Los Angeles CA, USA*
[6] *Department of Pathology and Laboratory Medicine, Cedars-Sinai Medical Center, Los Angeles CA, USA*
[7] *Department of Pathology, Intermountain Healthcare, Salt Lake City UT, USA*
[8] *Department of Pathology, Brigham and Women's Hospital, Boston MA, USA*
[9] *Department of Pathology and Laboratory Medicine, Mayo Clinic, Phoenix AZ, USA*
[10] *Department of Laboratory Medicine and Pathology, Mayo Clinic, Rochester MN, USA*
[11] *Department of Pathology, Johns Hopkins University School of Medicine, Baltimore MD, USA*
[12] *Department of Pathology, University Health Network, Toronto ON, CA*
[13] *Department of Pathology and Immunology, Washington University, St. Louis MO, USA*
[14] *Department of Pathology and Laboratory Medicine, The University of Texas Health Science Center at Houston, Houston TX, USA*
[15] *Department of Pathology, Massachusetts General Hospital, Boston MA, USA*
[16] *Pratt School of Engineering, Department of Electrical and Computer Engineering, Duke University, Durham NC, USA*

ARTICLE INFO

Article history:
Received 3 April 2023
Revised 15 April 2024
Accepted 16 April 2024

Keywords:
Cardiac transplantation
Antibody mediated rejection
Machine learning
Artificial intelligence

ABSTRACT

Background: Pathologic antibody mediated rejection (pAMR) remains a major driver of graft failure in cardiac transplant patients. The endomyocardial biopsy remains the primary diagnostic tool but presents with challenges, particularly in distinguishing the histologic component (pAMR-H) defined by 1) intravascular macrophage accumulation in capillaries and 2) activated endothelial cells that expand the cytoplasm to narrow or occlude the vascular lumen. Frequently, pAMR-H is difficult to distinguish from acute cellular rejection (ACR) and healing injury. With the advent of digital slide scanning and advances in machine deep learning, artificial intelligence technology is widely under investigation in the areas of oncologic pathology, but in its infancy in transplant pathology. For the first time, we determined if a machine learning algorithm could distinguish pAMR-H from normal myocardium, healing injury and ACR.

Materials and Methods: A total of 4,212 annotations (1,053 regions of normal, 1,053 pAMR-H, 1,053 healing injury and 1,053 ACR) were completed from 300 hematoxylin and eosin slides scanned using a Leica Aperio GT450 digital whole slide scanner at 40X magnification. All regions of pAMR-H were annotated from patients confirmed with a previous diagnosis of pAMR2 (>50% positive C4d immunofluorescence and/or >10% CD68 positive intravascular macrophages). Annotations were imported into a Python 3.7 development environment using the OpenSlide™ package and a convolutional neural network approach utilizing transfer learning was performed.

Results: The machine learning algorithm showed 98% overall validation accuracy and pAMR-H was correctly distinguished from specific categories with the following accuracies: normal myocardium (99.2%), healing injury (99.5%) and ACR (99.5%).

* Corresponding Author: Carolyn Glass, 217AM Davison Building, Box 3712, 40 Duke Medicine Circle, Department of Pathology, Duke University Medical Center, Durham NC 27710.

E-mail address: carolyn.glass@duke.edu (C. Glass).

https://doi.org/10.1016/j.carpath.2024.107646
1054-8807/© 2024 Elsevier Inc. All rights reserved.

Conclusion: Our novel deep learning algorithm can reach acceptable, and possibly surpass, performance of current diagnostic standards of identifying pAMR-H. Such a tool may serve as an adjunct diagnostic aid for improving the pathologist's accuracy and reproducibility, especially in difficult cases with high inter-observer variability. This is one of the first studies that provides evidence that an artificial intelligence machine learning algorithm can be trained and validated to diagnose pAMR-H in cardiac transplant patients. Ongoing studies include multi-institutional verification testing to ensure generalizability.
© 2024 Elsevier Inc. All rights reserved.

1. Introduction

Antibody mediated rejection (AMR) occurs in 10%-20% of cardiac transplant recipients and is undoubtedly associated with accelerated graft failure, and increased morbidity and mortality [1]. The incidence of AMR is expected to rise due to the increased number of pre-sensitized patients who have previously been supported by mechanical circulatory devices. AMR develops when recipient antibodies are directed against donor human leukocyte antigens (HLA) and possibly non-HLA on the endothelial layer of the allograft, inducing fixation and activation of the complement cascade [2].

To date, tissue diagnosis by endomyocardial biopsy remains the gold standard for pathologic AMR (pAMR), which is heavily relied upon by transplants cardiologists to correlate clinically significant AMR requiring plasmapheresis. The 2004 International Society for Heart and Lung Transplantation (ISHLT) revision of cardiac pAMR criteria details the two most important histologic criteria as 1) capillary injury with endothelial swelling and 2) intravascular macrophage accumulation. Ancillary studies to confirm these findings include immunofluorescence (IF) for deposition of immunoglobulin (IgG, IgM, and/or IgA) with complement (C1q, C4d, and/or C3d) on frozen section tissues, and CD68 staining of intracapillary macrophages or C4d staining of capillaries by immunohistochemistry (IHC) on paraffin-imbedded tissue. The 2013 ISHLT update expands these descriptions to include 1) accumulation of macrophages that distend the capillary and venule lumens and 2) enlarged endothelial nuclei and expanded cytoplasmic projections that either narrow or occlude the vascular lumens [3]. These descriptions were incorporated to clarify the histopathologic criteria for cardiac pAMR and reduce variability in the diagnosis.

The scoring system for pAMR includes both a histologic (pAMR-H) and immunopathologic component (pAMR-I). Diagnosing pAMR-H is based on evaluating cellular morphology by hematoxylin and eosin (H&E) staining and entails identifying the presence of the features described in the histologic ISHLT criteria. The recommended protocol for evaluation of the immunopathologic component on the endomyocardial biopsy include both frozen tissue for IF studies and paraffin IHC analysis to confirm deposition of complement on endothelium as well as infiltration of the intravascular macrophages. However, identifying pAMR-H, a qualitative morphologic assessment, can be much more challenging to diagnose than pAMR-I the immunologic component, and is associated with high inter-observer variability amongst even experienced cardiac pathologists [4]. Furthermore, unrecognized or misdiagnosis from inexperienced pathologists may lead to suboptimal treatment for transplant patients.

Detecting pAMR-H may be subtle and is most commonly mistaken for non-specific healing injury or the more frequent acute cellular rejection (ACR). Recent advances in digital pathology, such as the advent of whole slide scanners, faster computing power, increased and less expensive data storage options, and improved networking capabilities have allowed digital pathology to be applied to a wide variety of applications in the field of medicine. One such application that has gained wide traction in industry and academic settings is the application of machine learning algorithms in identifying disease processes using whole slide images (WSI) [5].

In particular, deep learning convolutional neural networks provide more accurate and robust network architectures than traditional machine learning approaches and have superior accuracy in image analysis applications [6-8]. Many image analyses tasks, such as segmentation, detection, counting, and tissue classification have been performed with greater accuracy than traditional machine learning methods and more accurately than humans. While much work has been in tissue classification in the area of neoplasia, there is a paucity of such investigations in the field of transplantation. We present here one of the first machine learning algorithms to our knowledge, developed to diagnose pAMR-H in cardiac transplant surveillance biopsies with a high degree of accuracy while distinguishing it from the more common form of rejection (ACR) and its benign histologic mimickers such as healing injury.

2. Materials and methods

2.1. Tissue procurement and processing for whole slide imaging

Following Institutional Review Board Approval, endomyocardial transplant biopsy tissue fragments previously as pAMR2 as part of routine standard of clinical care between 2018 and 2021 from Duke University Medical Center Department of Pathology were included in the study. Each case selected for annotation was previously diagnosed as pAMR2 with immunologic evidence of AMR based on either >50% endothelial deposition of C4d by IF, and/or >10% intravascular macrophages by CD68 or PU.1/CD31 double stain IHC.

All biopsy fragments were immediately stored in 10% neutral buffered formalin and embedded in paraffin immediately after procurement. Hematoxylin and eosin (H&E) staining was performed based on established recommendations by the Society of Cardiovascular Pathologists for transplant endomyocardial biopsies [9]. Slides were de-identified and underwent whole slide image (WSI) scanning using the Leica Aperio GT450 digital whole slide scanner [10] at 40X magnification. WSIs were transferred to a secure server, stored and accessed only by key Duke personnel.

2.2. Defining ground truth for supervised algorithm training

Because the histologic features of pAMR-H have been associated with high reported inter-observer variability, it is critical to define the ground truth to ensure high accuracy training based on expert consensus. In our study, the ground truth was defined by an expert consensus panel of 16 experienced cardiovascular pathologists associated with the Society of Cardiovascular Pathology. The critical and challenging nature of defining ground truth for a training set when designing a supervised machine algorithm for a diagnostic entity with high interobserver availability is well known [11,12].

The expert consensus group comprised of 16 cardiac pathologists across 12 different institutions in the United States and Canada was assembled to provide calibration on the histologic features of pAMR based on ISHLT published guidelines and define histologic ground truth. To ensure an accurate definition of ground truth, an expert was defined as a pathologist with 1) experience

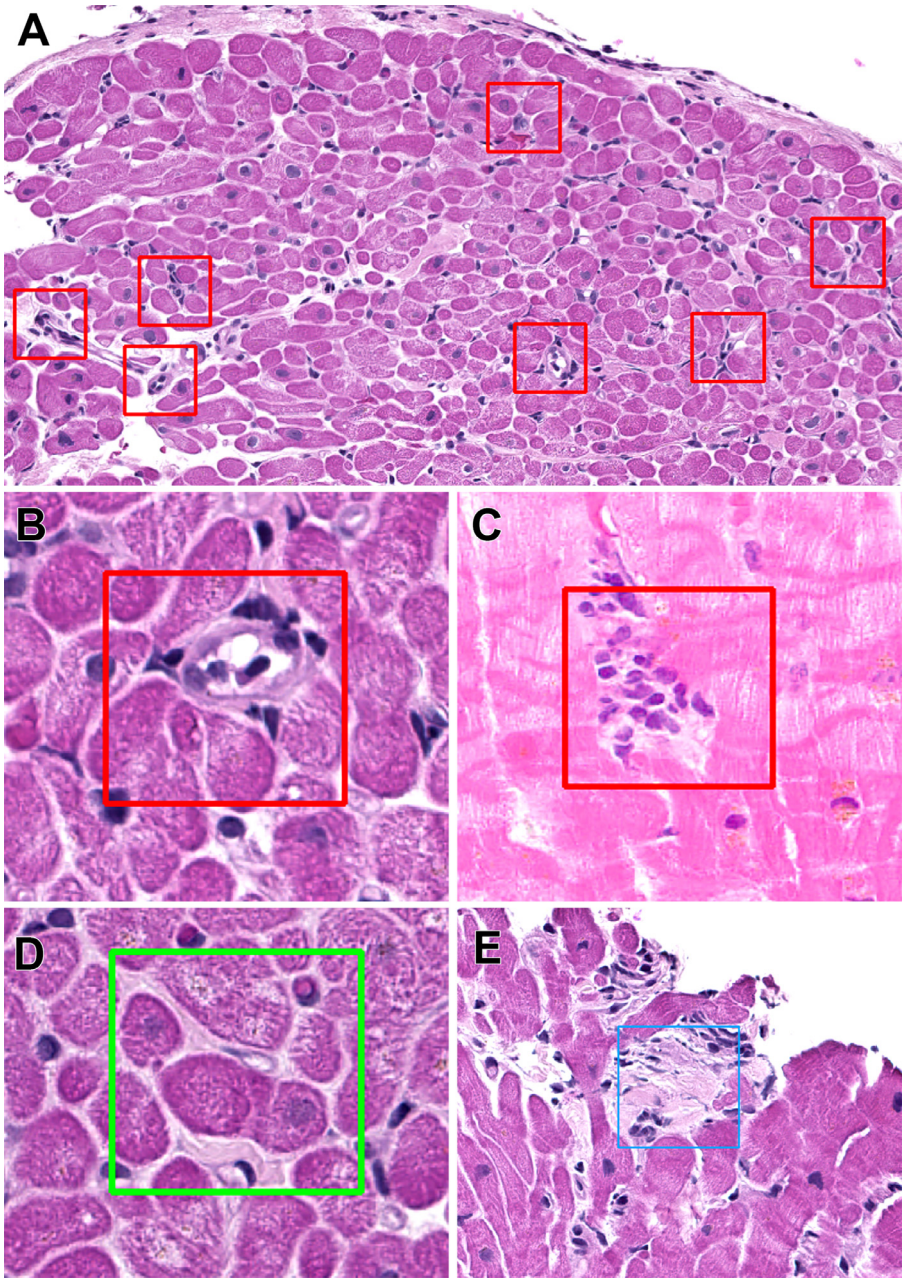

Fig. 1. a. Hematoxylin and eosin (H&E) stain of an endomyocardial heart transplant biopsy from the right ventricle scanned at 40X on the Leica GT450 scanner and photographed at 20x magnification. Pictured from top down is a thin endocardial layer with the underlying myocardial layer composed of bright pink cardiomyocytes. In between the cardiomyocytes is the interstitial (white) space which houses the capillaries. Histologic Antibody Mediated Rejection (pAMR-H) is a capillary centric phenomenon and annotation of the relevant areas is critical. Red squares denote multiple annotations completed for the algorithm training set. Within the red box includes a capillary (lined by endothelial cells) within the interstitial space surrounded by a few cardiomyocytes. The two main histologic features of AMR, endothelial swelling lining the capillaries and the presence of mononuclear/histiocytes within the capillary are points of interest for algorithm training. b. High magnification annotated region of interest with evidence of pAMR-H on H&E. Scanned and photographed at 40x magnification. c. High magnification annotated region of interest with Acute Cellular Rejection (ACR) on H&E. Scanned and photographed at 40x magnification. d. High magnification annotated region of interest of normal endomyocardium on H&E. Scanned and photographed at 40x magnification. e. High magnification annotated region of interest of healing injury with background fibrosis on H&E. Scanned and photographed at 40x magnification. (For interpretation of the references to colour in this figure legend, the reader is referred to the web version of this article.)

with a minimum of 5,000 cardiac transplant endomyocardial biopsies previously diagnosed, 2) fellowship training in cardiovascular pathology or over 10 years of experience diagnosing cardiac rejection or 3) faculty practicing at a high-volume cardiac transplantation institution (high volume defined as >50 transplants a year). The available expert pathologists represented the following 12 academic institutions: Brigham and Women's Hospital (Boston, MA), Cedars- Sinai Medical Center (Los Angeles, CA), Duke Medical Center (Durham, NC), Johns Hopkins (Baltimore, MD), Massachusetts General Hospital (Boston, MA), Mayo Clinic (Scottsdale, AZ), Mayo Clinic (Rochester, MN), University of California at Los Angeles (Los Angeles CA), University of Texas/Texas Heart Institute (Houston, TX), University of Toronto (Toronto, Canada), University of Utah/Intermountain Healthcare (Salt Lake City, UT) and Washington University (St. Louis, MO).

Through a 1:1 virtual meeting with the senior author, each of the 16 pathologists was shown 55 individual digitized open source histologic image patches previously diagnosed as pAMR-H, ACR,

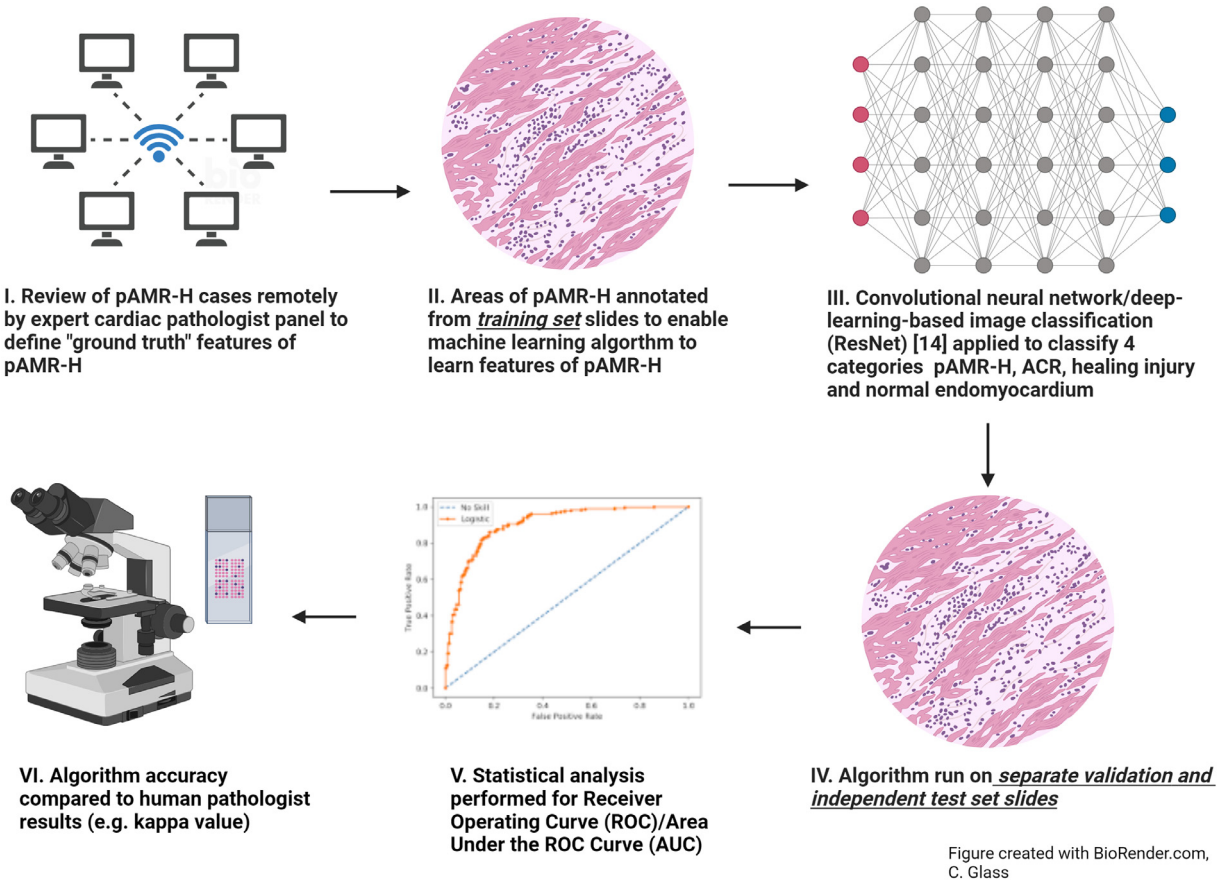

Fig. 2. Illustration summarizing the workflow for algorithm development.

healing injury or normal endomyocardium. Each pathologist was asked if they would render a diagnosis of pAMR-H on the digitized image/patch based on ISHLT criteria. The overall average concordance rate between the 16 pathologists for all 55 images was 94%. Of the 55 images shown, 46 images had perfect (100%) concordance. Nine images did not have perfect (100%) concordance; 3 images had 50% agreement, 1 had 63% agreement, 2 had 67% agreement, and 4 had 83% agreement. The lack of agreement in these 9 images was mainly due to *the degree of* endothelial swelling. After taking into account this specific histologic feature that contributed to the discordance, annotations for the training set were completed by the senior author. Care was taken to perform annotations that reflected only the stringent calibrated histologic criteria (definitive endothelial swelling and the presence of intracapillary macrophages, defined as the ground truth) clearly agreed upon by the expert panel.

2.3. Algorithm training, validation and testing

The Leica Biosystems® Aperio ImageScope™ pathology viewing software [13] was used to view and annotate specific regions of interest on the slide. A total of 4,212 manual annotations (1,053 regions of normal, 1,053 pAMR-H, 1,053 healing injury and 1,053 ACR) were completed from 300 H&E stained slides scanned using a Leica Aperio AT2 digital whole slide scanner at 40X magnification (Fig. 1a-e). All regions of pAMR-H were annotated from patients confirmed with pAMR2 (>50% positive C4d immunofluorescence and/or >10% CD68 positive intravascular macrophages). A four-layered annotation system of histologic primitives was used to divide annotations into normal, healing injury, pAMR-H and ACR regions of interest using Leica ImageScope Software. Using non-overlapping 224 × 224 windows for each patch with a specific color designation at 40x magnification, a supervised learning approach with a convolutional neural network model was used to develop the algorithm (Fig. 2).

Within each of the four categories (normal, healing injury, ACR and pAMR-H), images were randomly split into training, validation and testing sets, consisting of 70%, 10%, and 20% of all images, respectively. The deep-learning-based image classification method, ResNet [14], was applied to classify the four category status simultaneously, or to classify between pAMR-H and each of the remaining three categories. ResNet50 model was implemented using the Python torchvision package [15] (version 0.14.1), part of the PyTorch project. The pre-trained weights of ResNet50_Weights provided by torchvision was used to initialize the model. The model was then fine-tuned using the training images in this study with a cross entropy loss, Adam optimizer [16] and a learning rate of 0.0001. The model training was stopped when the loss calculated on the validation set stopped improving. The trained model was applied to the testing set to generate predicted probabilities. Receiver operating characteristic (ROC) curves and area under the ROC curve (AUC) were obtained by the R package pROC [17] (version 1.18.0).

2.4. Comparison of human pathologist performance

Three pathologists at Duke University Medical Center blinded to the previous diagnosis were asked to independently review a separate curated set of 20 H&E stained glass slides (previously diagnosed as pAMR2 with confirmed >50% C4d IF positivity). Each pathologist was asked to state based on the H&E alone, whether

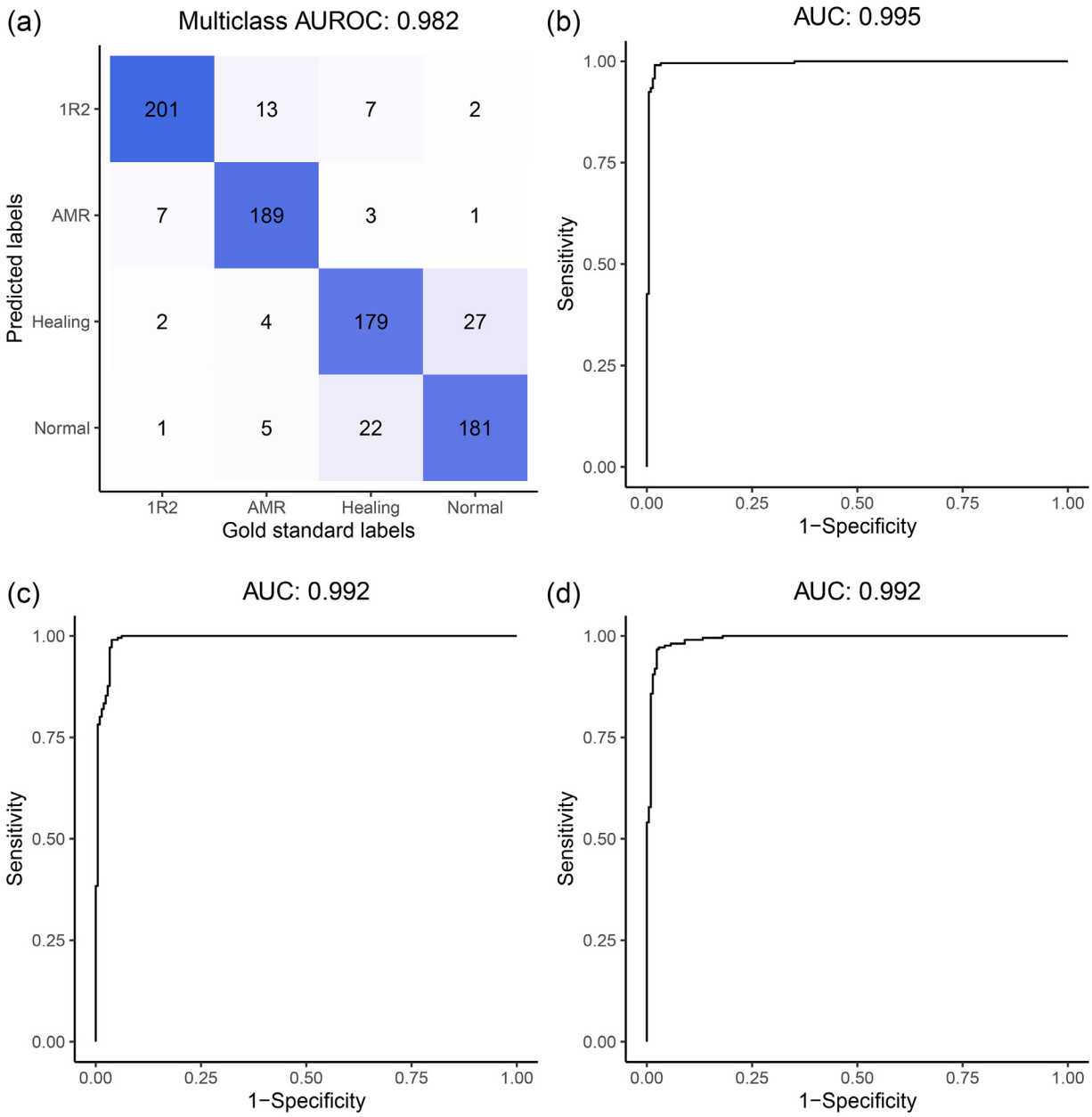

Fig. 3. a. Area Under the Receiver Operating Curve (AUC) is a graphical representation of the performance of a binary classification model of various classification thresholds. AUC for the overall algorithm is depicted in this figure. b. The AUC for histological AMR versus normal endomyocardium. c. The AUC for histologic AMR versus healing injury. d. The AUC for histologic AMR versus acute cellular rejection.

they would diagnose the presence of pAMR-H, ACR, both pAMR-H and ACR (mixed), healing injury or normal endomyocardium.

3. Results

With all four categories, the algorithm showed 98% overall validation accuracy (Fig. 3a). pAMR-H was then distinguished from normal myocardium, healing injury and ACR with 99.5%, 99.2% and 99.2% accuracy, respectively (Figs. 3b-d).

The kappa values between the human pathologist review of pAMR-H ranged from 0.10 to 0.65. There was concordance on the presence of pAMR-H between all pathologists in 88% of the cases. However, if there was concurrent background healing injury associated with pAMR-H, the concordance between the three pathologists for pAMR-H decreased to 70%. In cases with both pAMR-H and ACR (mixed rejection), the concordance rate further dropped to 65% agreement.

4. Discussion

Accurately identifying pAMR-H, a qualitative morphologic assessment, is critical for the diagnosis of cardiac transplant rejection. If unrecognized, suboptimal treatment may ensue.

We trained a convolutional neural network to distinguish AMR-H from benign mimicks such as healing injury, ACR, and normal myocardium with an overall 98% accuracy.

Based on a review of cases by an expert consensus panel of cardiac pathologists, discordant opinions on the degree of endothelial swelling are a major contributor to the high interobserver variability. The kappa values in a human pathologist review of pAMR-

H ranged from 0.10 to 0.65. Interestingly, if there was concurrent background healing injury associated with pAMR-H, the concordance for diagnosing pAMR-H markedly decreased from 88% to 70%, highlighting the difficulty with distinguishing healing injury from pAMR-H. Furthermore, our study showed human pathologist concordance decreased even more in cases with both pAMR-H and ACR (mixed rejection) with 65% agreement. These results support the potential benefits of an algorithm that is able to distinguish pAMR-H from healing injury with 99.2% accuracy (AUC 0.992) and from ACR with 99.2% accuracy (AUC 0.992). The algorithm also shows promise when compared to Hammond et al's study [18] of 768 biopsies reviewed by humans with confirmed positive C4d IF which showed sensitivity of identifying histologic evidence of significant endothelial swelling (feature of AMR-H) on H&E alone of 63% and specificity of 80%, and sensitivity of histologic evidence of significant intracapillary macrophages (feature of AMR-H) on H&E alone of 30% and specificity of 99%.

Although pAMR occurs with less frequency than ACR, it is the more aggressive form of rejection associated with accelerated graft dysfunction, cardiac allograft vasculopathy and mortality. A strength of our study was the volume of available histologic data available to develop a robust training algorithm. As one of the highest volume cardiac transplantation centers in the country, the histologic data and digital infrastructure is well streamlined at our institution. We opted for the supervised approach for training the machine learning algorithm due to the available diagnostic expertise of the multi-institutional expert group of cardiac pathologists across 12 institutions.

Although our validation accuracy of diagnosing AMR-H is promising, whether the reliability of an AI-assisted algorithm can convince pathologists to diagnose AMR based on histologic features alone and drop the immunologic component of the ISHLT criteria will likely not be considered standard of practice in the near future without further reproducible investigations.

A limitation of our study is the algorithm was developed and validated using specific annotated regions of the slide (patches). It is anticipated the accuracy level would be reduced when performing at the whole slide level. Only one other (recent) study has developed a similar algorithm addressing diagnosing AMR using machine learning. Lipkova et al [18] developed a machine learning-based system for automated assessment of gigapixel whole-slide images obtained from endomyocardial transplant biopsies. In his study, the model detects AMR with an AUC of 0.874 at the whole slide level. In the human reader study, the algorithm system showed non-inferior performance to conventional assessment and reduced interobserver variability and assessment time. However, this particular study did not address the specific diagnostic challenge of distinguishing pAMR-H from healing injury, which is a very real diagnostic challenge when reviewing and diagnosing endomyocardial transplant biopsies. Another limitation of this study is the technical generalizability of the study; all slides were processed and stained at a single institution (Duke). To further assess our model performance, larger pAMR-H datasets and test cohorts, including IHC double staining from three additional cardiac transplant institutions (Cedars-Sinai Medical Center Department of Pathology and Laboratory Medicine, Intermountain Healthcare Department of Pathology, and Mass-Brigham and Women's Hospital Department of Pathology) have been curated for future digitization. Further testing of our algorithm on these independent cohorts will improve generalizability and address issues of any large-scale variability across populations, sample preparations and slide scanning instrumentation.

The current landscape of published literature on AI applications for pathologic image analysis is centered in oncology [19-21], with only a handful of studies focusing on the field of transplantation. AI applications in cardiac transplantation are sparse but interest is steadily growing. For the purposes of future clinical adoption of these AI-assisted machine learning algorithms, we favor development of such tools using the supervised (annotation) method with consensus input from expert pathologists.

In conclusion, AI-assisted algorithms have the potential to provide meaningful improvement in pathologic diagnostic accuracy, efficiency and reproducibility, particularly for cases associated with higher interobserver variability. However, a systematic approach that integrates quality assurance metrics for training machine algorithm tools is critical.

Declaration of competing interest

None.

CRediT authorship contribution statement

Matthew Glass: Writing – review & editing, Writing – original draft, Methodology, Investigation, Formal analysis, Data curation, Conceptualization. **Zhicheng Ji:** Validation, Formal analysis. **Richard Davis:** Methodology, Formal analysis. **Elizabeth N. Pavlisko:** Validation. **Louis DiBernardo:** Formal analysis. **John Carney:** Formal analysis. **Gregory Fishbein:** Validation, Formal analysis. **Daniel Luthringer:** Validation, Formal analysis. **Dylan Miller:** Validation, Formal analysis. **Richard Mitchell:** Validation, Formal analysis. **Brandon Larsen:** Validation, Formal analysis. **Yasmeen Butt:** Validation, Formal analysis. **Melanie Bois:** Validation, Formal analysis. **Joseph Maleszewski:** Validation, Formal analysis. **Marc Halushka:** Validation, Formal analysis. **Michael Seidman:** Validation, Formal analysis. **Chieh-Yu Lin:** Validation, Formal analysis. **Maximilian Buja:** Formal analysis, Writing – review & editing. **James Stone:** Validation, Formal analysis. **David Dov:** Methodology, Formal analysis. **Lawrence Carin:** Supervision, Resources. **Carolyn Glass:** Writing – review & editing, Writing – original draft, Supervision, Resources, Project administration, Methodology, Investigation, Data curation, Conceptualization.

References

[1] Hammond MEH, Revelo MP, Miller DV, et al. ISHLT pathology antibody mediated rejection score correlates with increased risk of cardiovascular mortality: a retrospective validation analysis. J Heart Lung Transpl 2016;35(3):320–5.
[2] Jackson AM, Glass C. Rejection in the setting of non-HLA antibody: New tools for navigating bench to bedside. Am J Transpl 2020;20(10):2639–41.
[3] Berry GJ, Burke MM, Andersen C, et al. The 2013 International Society for Heart and Lung Transplantation Working Formulation for the standardization of nomenclature in the pathologic diagnosis of antibody mediated rejection in heart transplantation. J Hear. Lung Transpl. 2013;32:1147–62.
[4] Glass C, Butt YM, Gokaslan ST, Torrealba JR. CD68/CD31 immunohistochemistry double stain demonstrates increased accuracy in diagnosing pathologic antibody-mediated rejection in cardiac transplant patients. Am J Transpl 2019;19(11):3149–54.
[5] Khened M, Kori A, Rajkumar H, et al. A generalized deep learning framework for whole slide image segmentation and analysis. Sci Rep 2021;11:11579.
[6] Madabhushi A, Lee G. Image analysis and machine learning in digital pathology: challenges and opportunities. Med Image Analysis 2016;33:170–5.
[7] Niazi MKK, Parwani AV, Gurcan MN, et al. Digital pathology and artificial intelligence. Lancet Oncol 2019;20:e253–61. doi:10.1016/S1470-2045(19)30154-8.
[8] Janowczyk A, Madabhushi A. Deep learning for digital pathology image analysis: a comprehensive tutorial with selected use cases. J. Pathol. Inform. 2016;7:29.
[9] Stewart S, Winters GL, Fishbein MC, et al. Revision of the 1990 working formulation for the standardization of nomenclature in the diagnosis of heart rejection. In: Journal of Heart and Lung Transplantation, 24. Elsevier; 2005. p. 1710–20.
[10] https://www.leicabiosystems.com/digital-pathology/scan/aperio/.
[11] Chen PC, Mermel CH, Liu Y. Evaluation of artificial intelligence on a reference standard based on subjective interpretation. Lancet Digit Health 2021;3(11):e693–5.
[12] Glass C, Lafata KJ, Jeck W, Horstmeyer R, Cooke C, Everitt J, Glass M, Dov D, Seidman MA. The role of machine learning in cardiovascular pathology. Can J Cardiol. 2022;38(2):234–45.
[13] https://www.leicabiosystems.com/digital-pathology/manage/aperio-imagescope/.

[14] He K, Zhang X, Ren S, Sun J. Deep residual learning for image recognition. In: Proceedings of the IEEE conference on computer vision and pattern recognition; 2016. p. 770–8.
[15] Marcel S, Rodriguez Y. Torchvision the machine-vision package of torch. In: Proceedings of the 18th ACM international conference on Multimedia; 2010. p. 1485–8.
[16] Kingma DP, Ba J. Adam a method for stochastic optimization. arXiv preprint 2014. arXiv:1412.6980.
[17] Robin X, Turck N, Hainard A, et al. pROC: an open-source package for R and S+ to analyze and compare ROC curves. BMC Bioinformatics 2011;17(12):77.
[18] Hammond ME, Stehlik J, Snow G, et al. Utah Transplant Affiliated Hospitals (UTAH) Cardiac Transplant Program. Utility of histologic parameters in screening for antibody-mediated rejection of the cardiac allograft: a study of 3,170 biopsies. J Heart Lung Transplant 2005;24(12):2015–21.
[19] Lipkova J, Chen TY, Lu MY, et al. Deep learning-enabled assessment of cardiac allograft rejection from endomyocardial biopsies. Nat Med 2022;28(3):575–82.
[20] Lee C, Light A, Alaa A, et al. Application of a novel machine learning framework for predicting non-metastatic prostate cancer-specific mortality in men using the Surveillance, Epidemiology, and End Results (SEER) database. Lancet Digit Health 2021;3(3):e158–65.
[21] Sammut SJ, Crispin-Ortuzar M, Chin SF, et al. Multi-omic machine learning predictor of breast cancer therapy response. Nature 2022;601(7894):623–629.